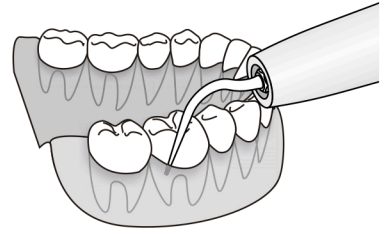
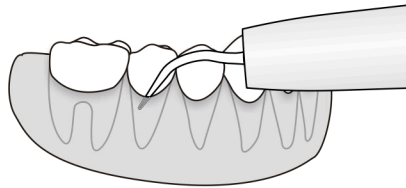
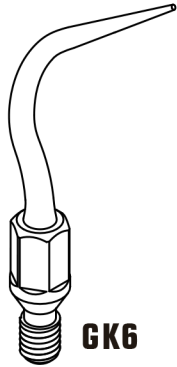
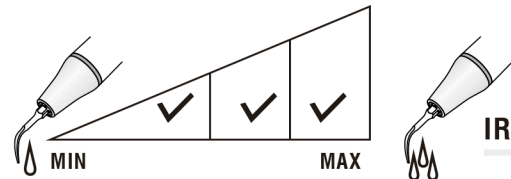
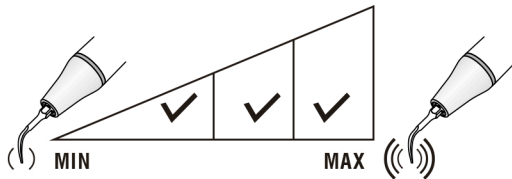


GK6

Left-angled, removal of subgingival calculus.



POWER



IRRIGATION